Canine Non-Ulcerative Corneal Diseases

Erin Gunderson, DVM, DACVO
Eye Care for Animals
October 8, 2013

Corneal Clarity

Transparency and transmission of light is maintained by the following corneal properties:

1. Avascular
2. Lack of pigmentation
3. Relative acellularity
4. Nonkeratinized surface epithelium
5. Relative dehydration (75-85% water)
6. Small size and organization of stromal collagen fibrils

Corneal Pathologic Responses

- Blood vessels
  - How fast do they grow?
- Edema
- Pigment
- Lipid, cholesterol or calcium
- Inflammatory cells
- Enzymatic destruction
- Scarring

Diagnostic Considerations

- Always fluorescein stain eye
  - With divots consider pooling of stain
- Consider Schirmer tear test
- Assess palpebral reflex, corneal (periocular sensation)
- Assess vision (menace response, dazzle reflex, PLR–direct and consensual)
- Explore for aberrant cilia, FB behind TEL, etc.
- Other tests as deemed necessary (i.e., cytology, culture, TFBUT)

Chronic Superficial Keratitis (Pannus)

- German Shepherd and Greyhound
- Bilateral and often symmetrical
- Controlled rather than cured
- Atypical pannus

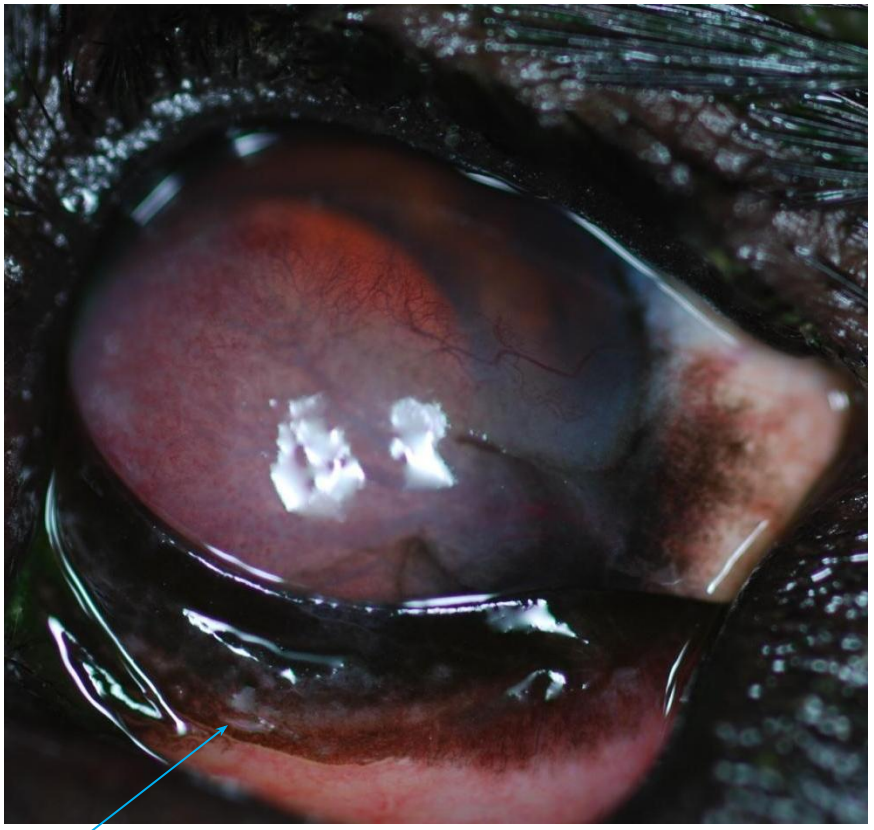

Pink nodules (aka plasmoma) on TEL = Atypical pannus or Immune-meditated

Chronic Superficial Keratitis (Pannus)

- 1% prednisolone or 0.1% dexamethasone
- 1% cyclosporine or 0.02% tacrolimus
- Subconjunctival steroid
- Other
  - Reduce UV exposure
  - Beta irradiation
  - Keratectomy

Depigmentation of TEL margin = Atypical Pannus

Episcleritis/Scleritis

- Cocker Spaniel and Airedale Terrier
- Regional or diffuse swelling
- Can mimic neoplasia
- Biopsy to confirm?

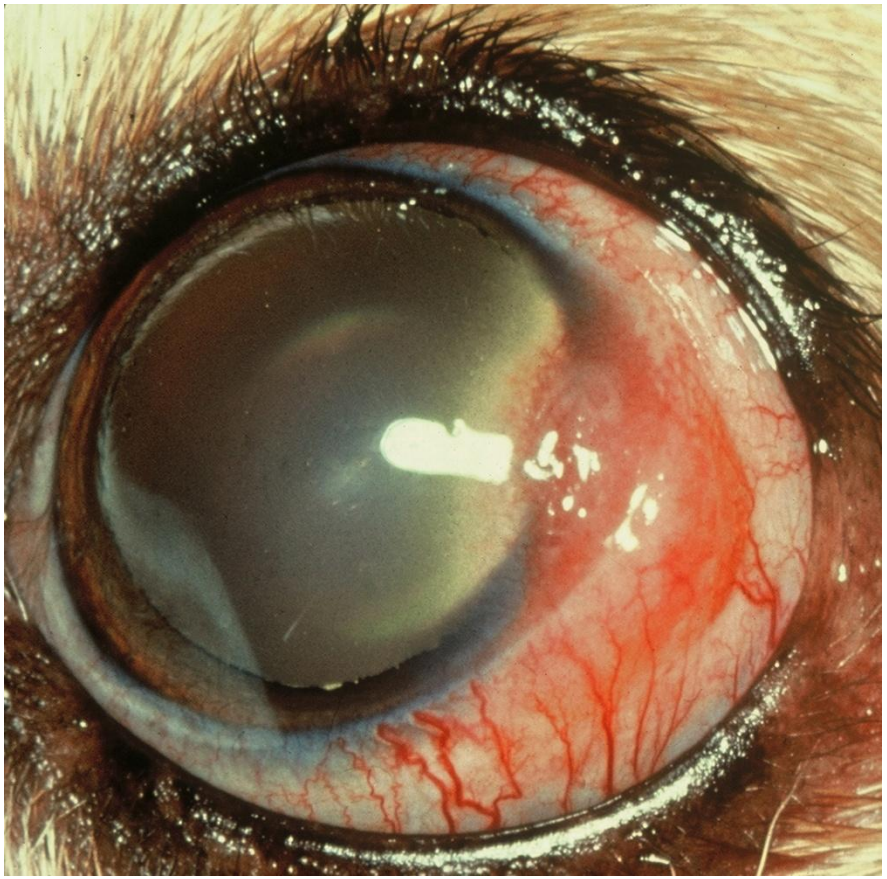

Episcleritis/Scleritis

- Tacrolimus or CSA
- Subconjunctival or topical steroid
- Oral azathioprine, prednisone, or cyclosporine
- Oral tetracycline and niacinamide

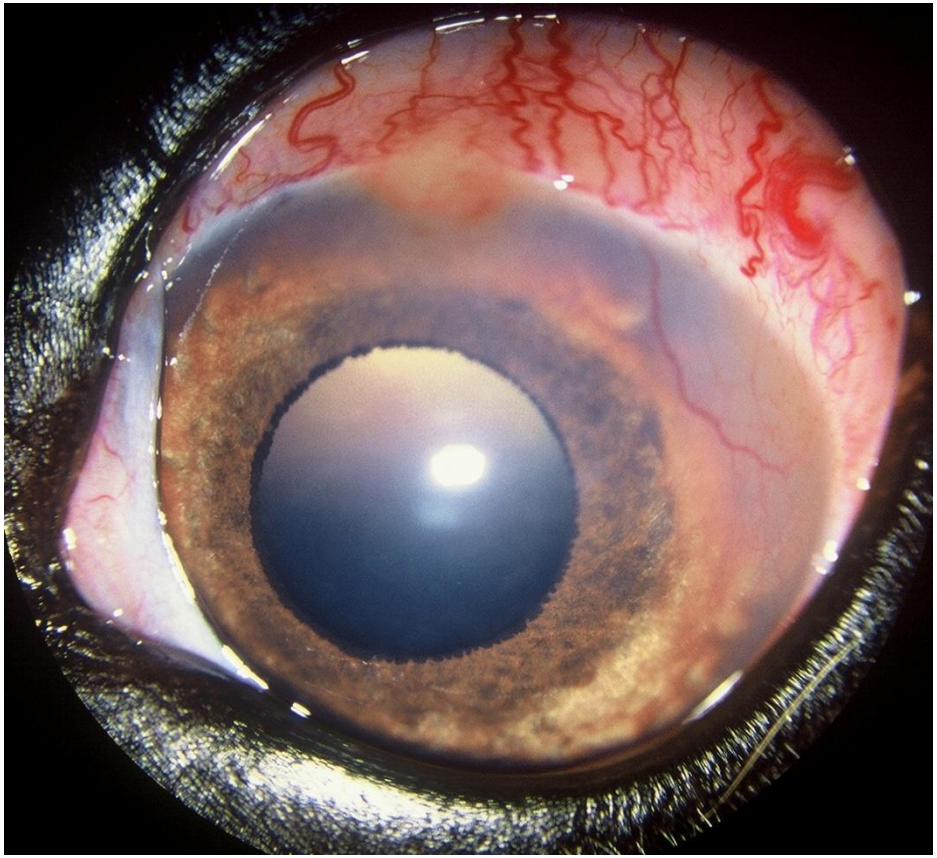

Pigmentary Keratitis

- Common with KCS
- Primary condition in the Pug
  - Genetic
- Breed-related exophthalmos and lagophthalmos
- Nasal trichiasis and entropion

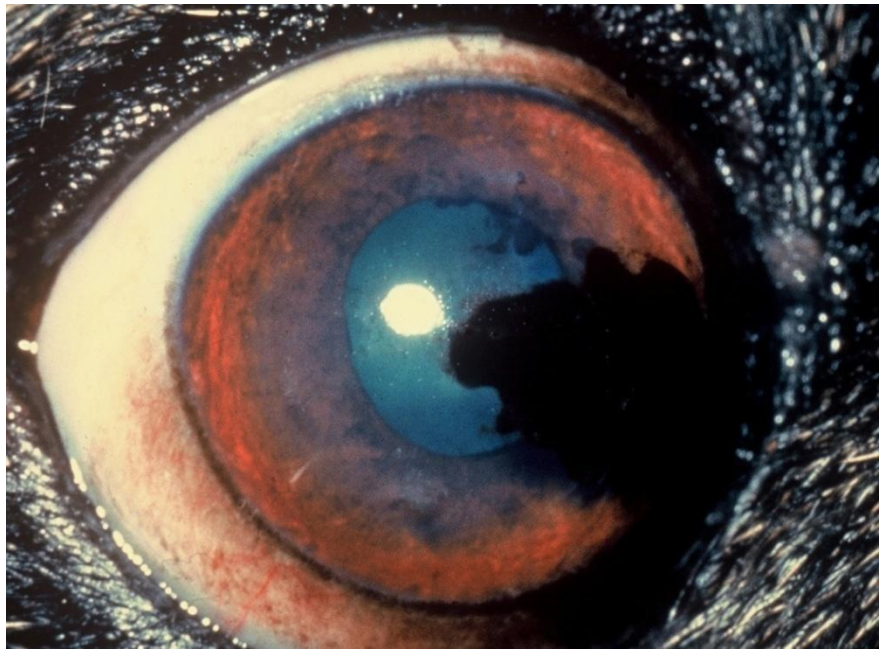

Pigmentary Keratitis

- Topical cyclosporine, tacrolimus, steroid*
- Nasal canthoplasty
- Lamellar or CO2 laser keratectomy?

Corneal Endothelial Dystrophy

- Predilection for Boston Terrier, Dachshund and Chihuahua
- Non-ulcerative initially
- Usually bilateral
- Generally starts at lateral limbus medially
- Progressive edema and bullous keratopathy

Corneal Endothelial Dystrophy

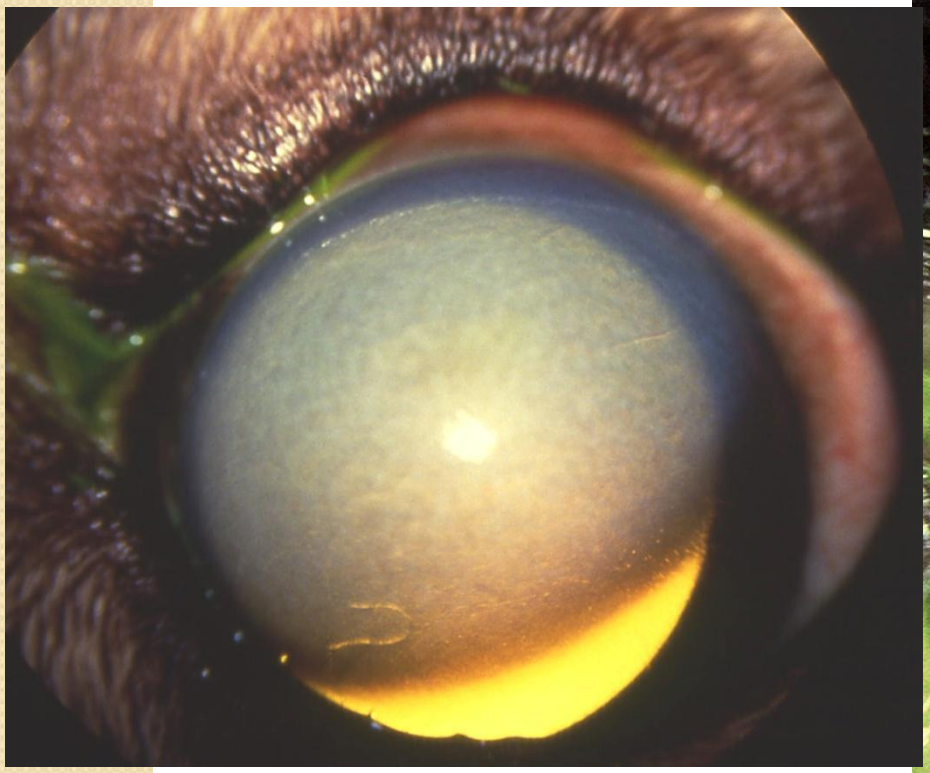

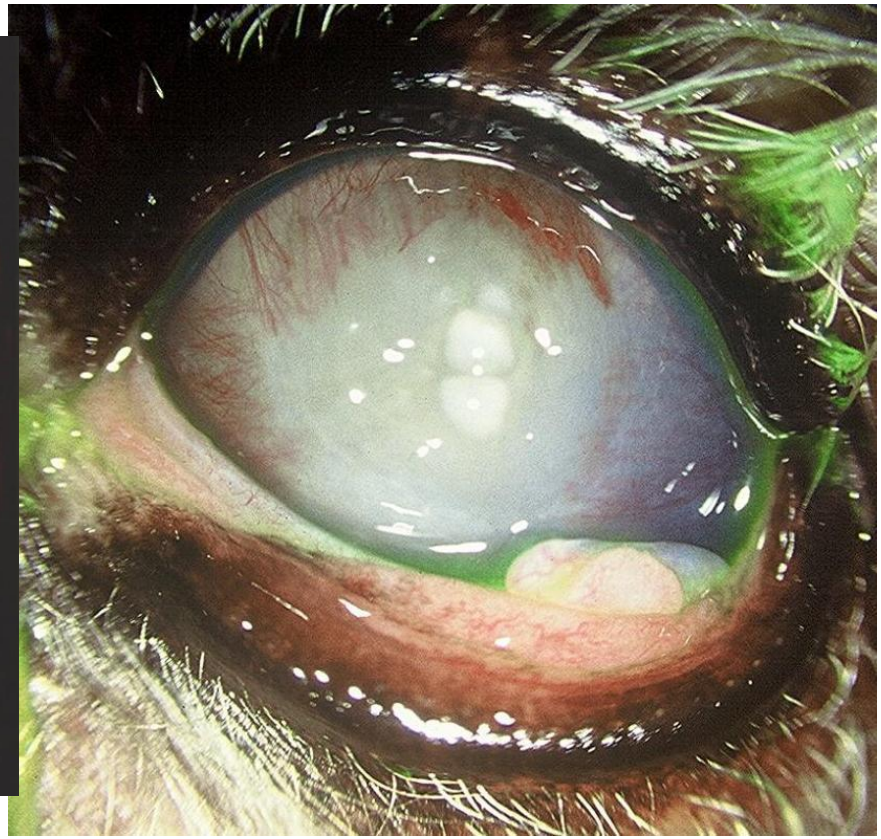

Corneal Endothelial Dystrophy

- Hyperosmotic ointment or drops
- Topical antibiotic/atropine - if ulcerated
- Topical flurbiprofen - decrease inflammation

Corneal Endothelial Dystrophy

- Thermal cautery (or thermokeratoplasty)
- Penetrating keratoplasty
- Keratoprosthesis
- Corneal endothelial transplant (humans)

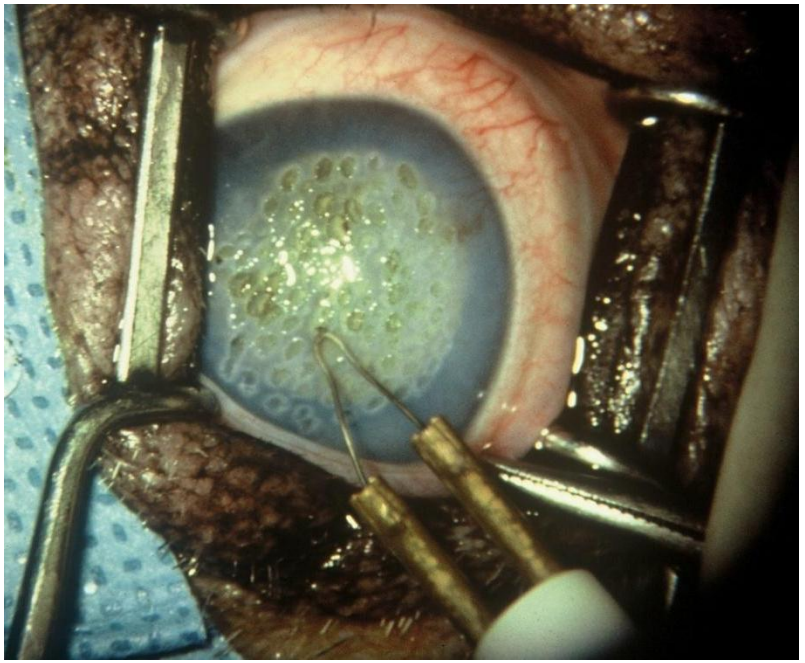

Penetrating Keratoplasty and Corneal Implants

- Rarely performed
- Donor cornea can be obtained overnight
- Success not as good as for people

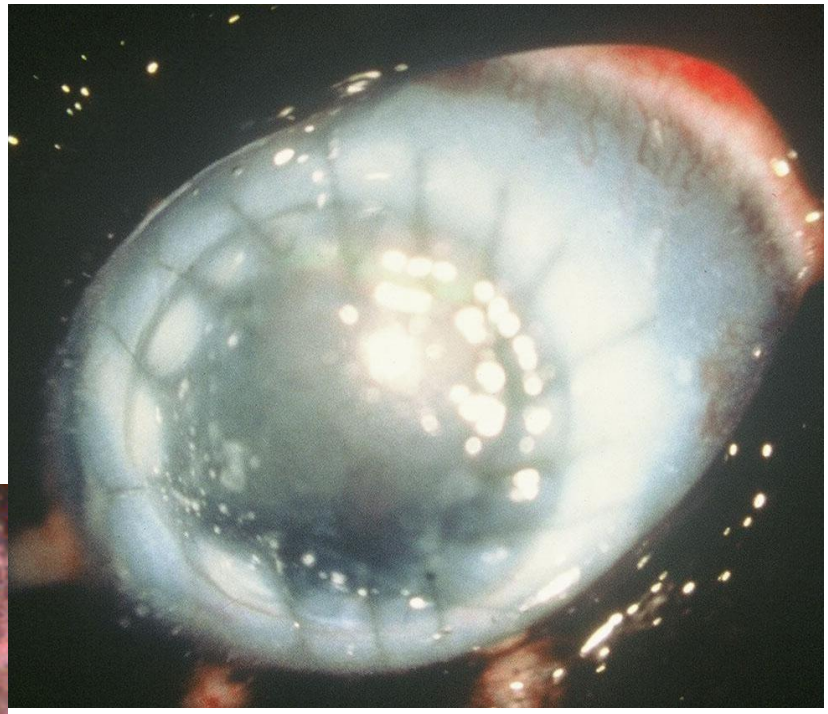

Penetrating keratoplasty

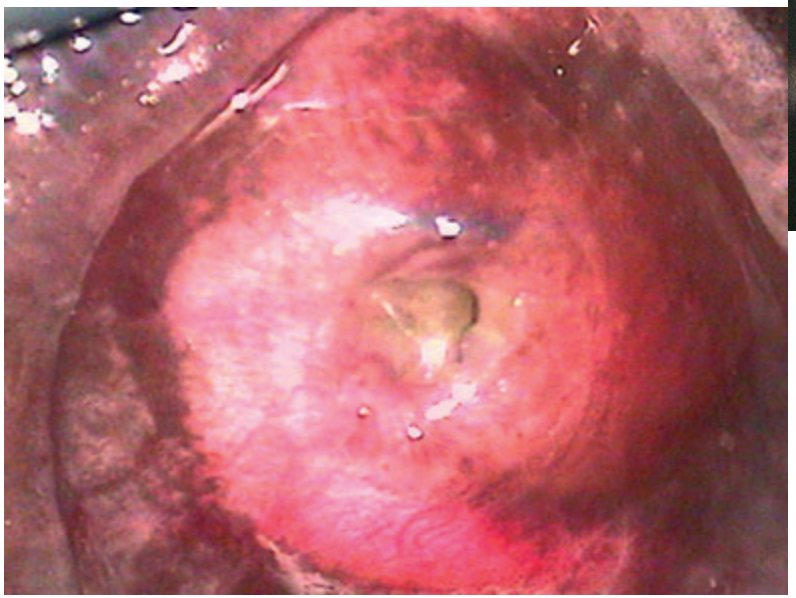

Granulation tissue after biosynthetic corneal implant

SASKATCHEWAN

ARIZONA

WISCONSIN



Corneal Dystrophy

- Breed predisposition
- Husky, Cavalier King Charles Spaniel, Airedale Terrier, Collie
- Genetic, developmental
- Calcium, Lipid, Cholesterol
- Check biochemical profile and lipids

Lipid Keratopathy

- Certain breed predilections
- Usually non-painful
- Minimal effect on vision
- Lipid, cholesterol or calcium
- Check biochemical profile and lipids
  - Endocrine diseases
- Low fat diet/treats?

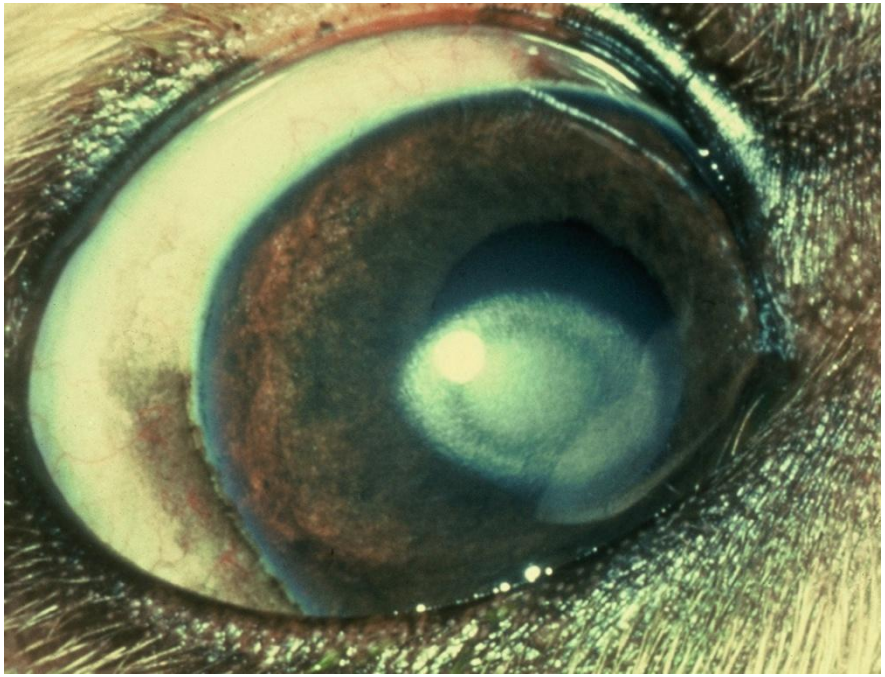

Lipid Corneal Dystrophy

Corneal Degeneration

- Lipid, cholesterol or calcium
- Often other ocular pathology
- Concurrent ulcers possible
- Can be painful and affect vision
- Check biochemical profile and lipids

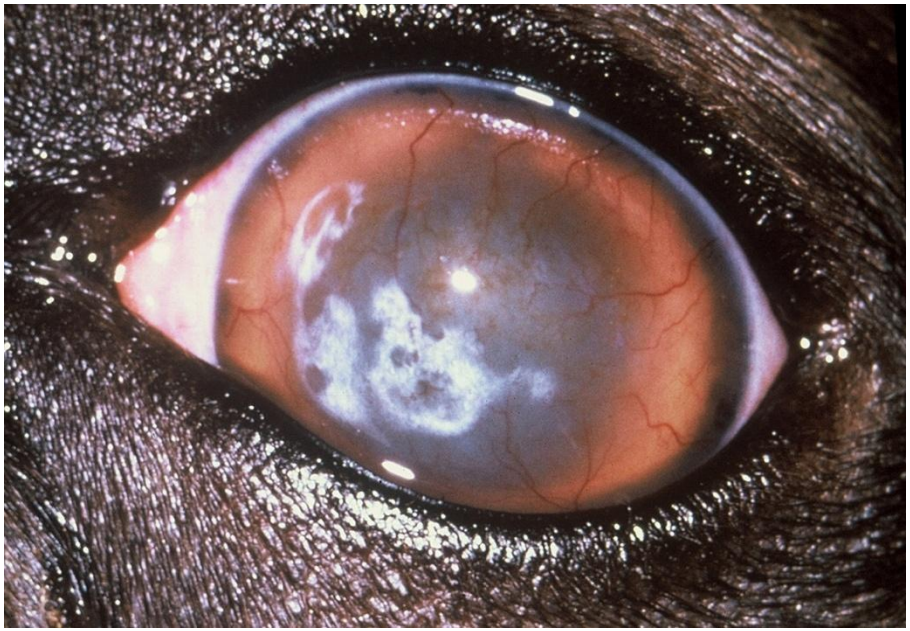

Corneal Degeneration

- Treat primary condition
- Topical EDTA solution
  - Ulcerated areas only?
- Tacrolimus/CSA?
- Trichlorocetic acid debridement
- Keratectomy and graft
- Low fat diet/treats?
- Omega-3 FA?

Sheltie Corneal Dystrophy

- Unique to breed
- Multiple circular opacities
- Variable ulceration
- Treatment with cyclosporine and/or steroids

Sheltie Dystrophy

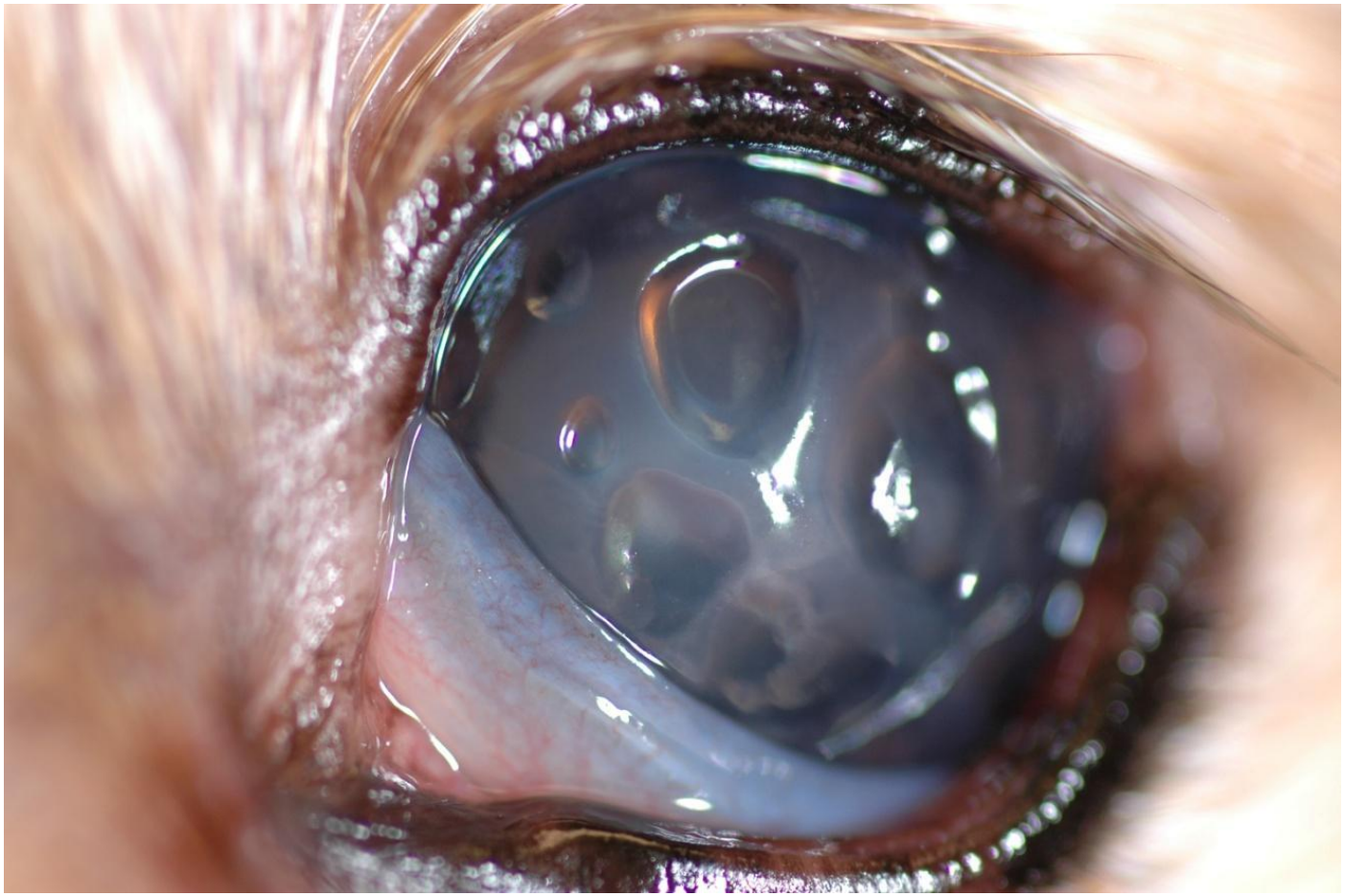

Superficial Punctate Keratitis

- Immune-mediated
- Steroid-responsive
  - Tacrolimus/CSA
- Dachshund, Sheltie, rarely other breeds

Corneal/Scleral Neoplasms

- Limbal Melanoma
  - Benign growths
  - Can become locally invasive
  - Dogs and cats
  - R/O uveal melanoma
  - German Shepherd, Labrador Retriever*

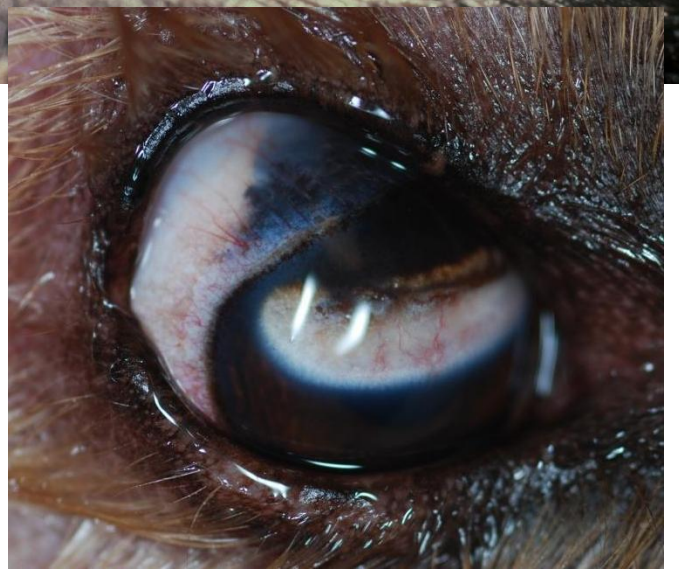

Corneal/Scleral Neoplasms

- Fibrous Histiocytoma
  - Primarily Collies
  - Immune-mediated granulomatous inflammation with variable fibrosis
  - Topical steroids
  - Azathioprine

Dermoids

- Benign growths
- Dogs and cats
- German shepherd
  Dalmatian
- Superficial
  keratectomy

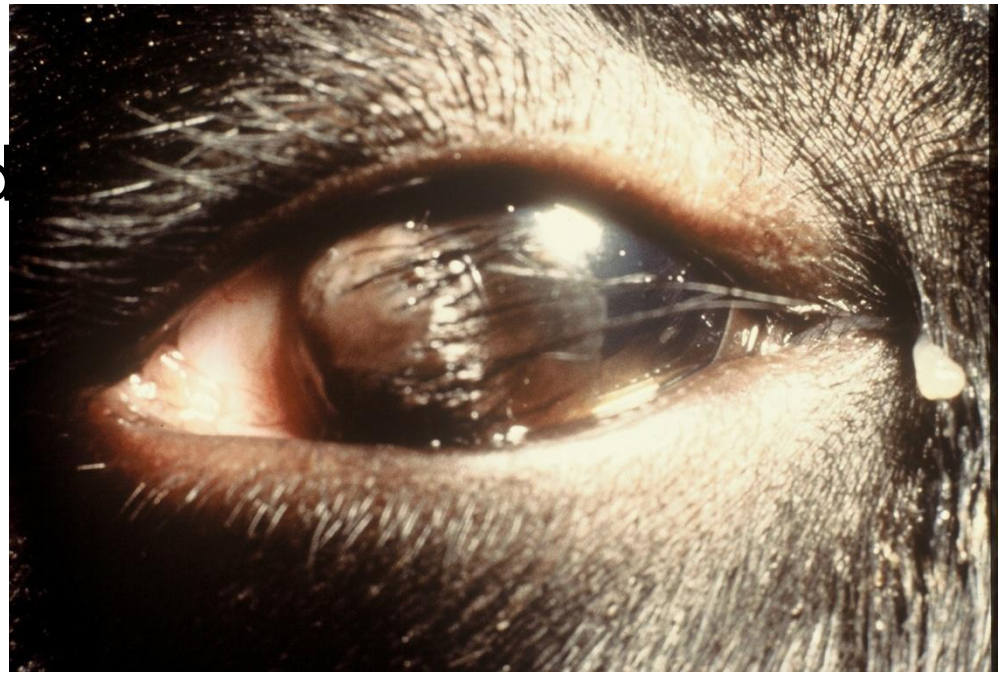

Erin Fralish, DVM, DACVO

Simple Ulcers

- Usually due to mild superficial trauma
- Only involves epithelium
- Broad spectrum antibiotics TID-QID
  - BNP oint, Gentamicin
- Consider serum, especially in brachycephalics
- Heal within 48-72 hours

Spontaneous Chronic Corneal Epithelial Defects (SCCED)

- AKA indolent ulcers AKA Boxer ulcer
- Non-healing (> 14 days) ulcer involving only an epithelial defect
- A non-adherent lip of epithelium is observed surrounding the central defect
- Age-related
- Boxers, Golden Retrievers
- Failure of the epithelium to ac

to the underlying stroma

- Variable vascularization

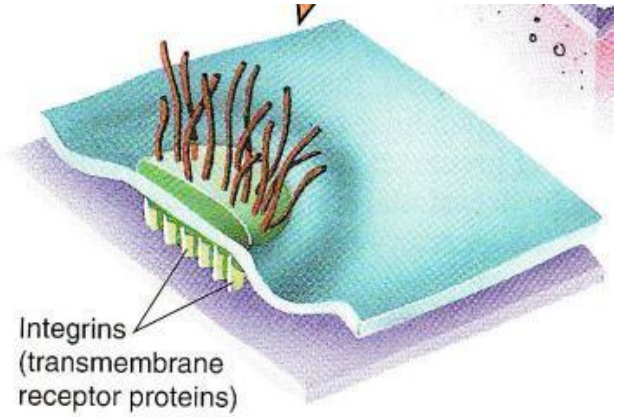

Medical Treatment

- Topical broad-spectrum antibiotic
- Oral pain medications
- NaCl ointment???
- Remend???
  - Facilitates cell migration and proliferation
- Simple debridement
  - Cotton-tip applicator and topical proparacaine

- Will heal without keratotomy
  - Average:
  - Vision loss due to vascularization/fibrosis

Debridement

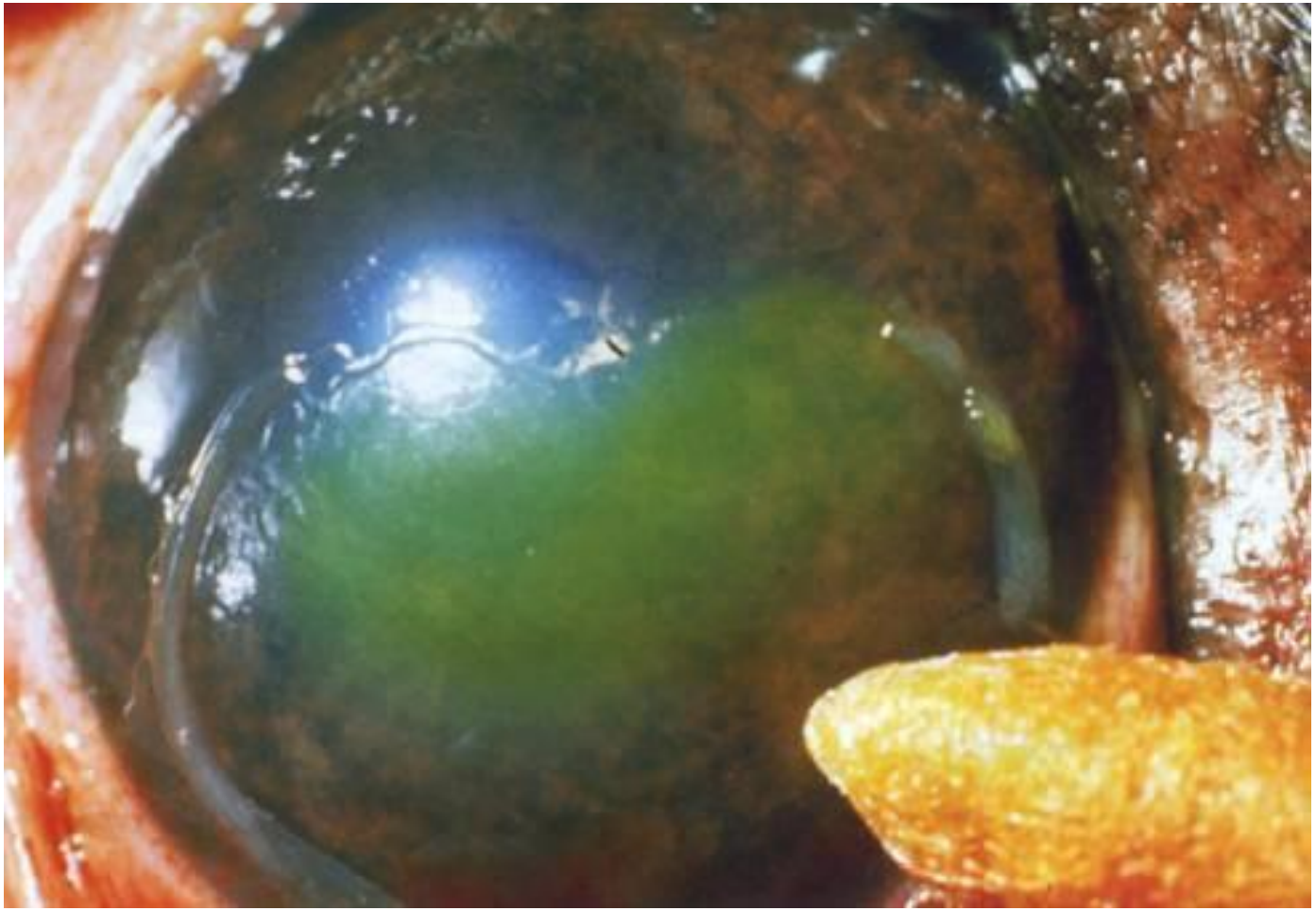

Surgical Treatment

- Linear grid keratotomy
  - Under general anesthesia here
  - Debridement with blade + Grid with 25g needle
  - Variation=superficial punctate keratotomy
- Superficial keratectomy
  - General anesthesia
  - Remove epithelium and anterior stroma with blade
- Diamond burr keratectomy

- ***No keratotomies in cats***

Grid-keratotomy

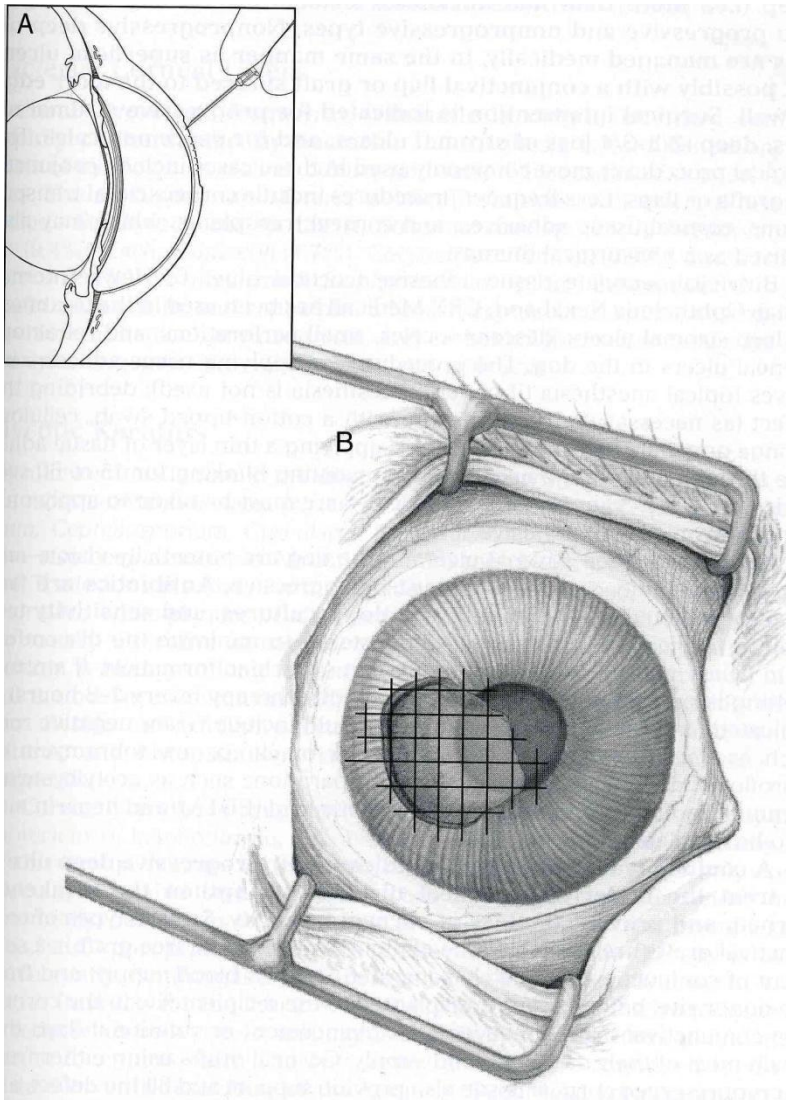

Grid-keratotomy

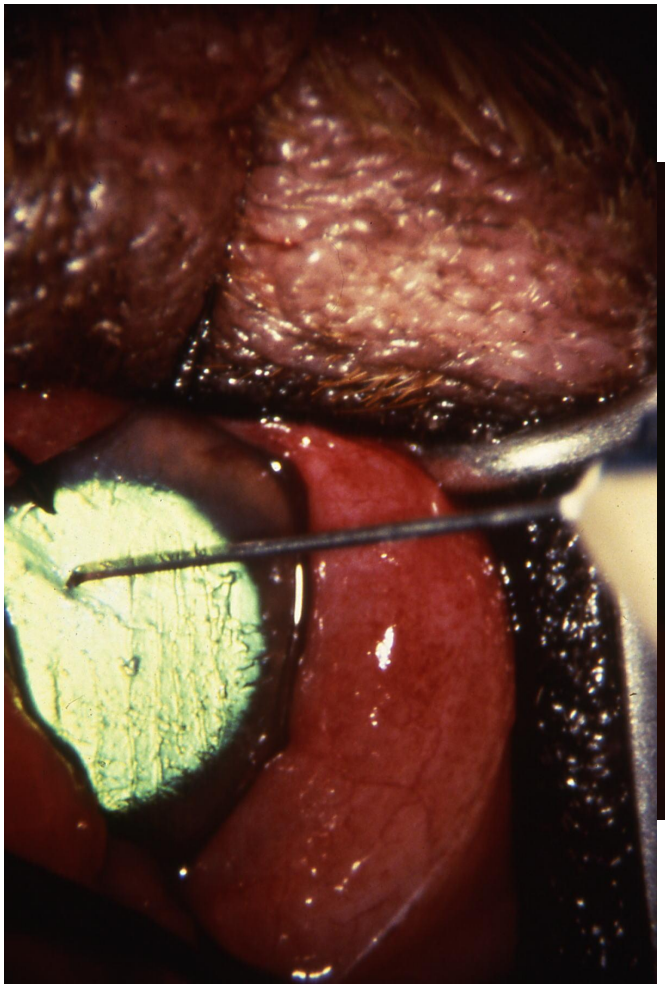

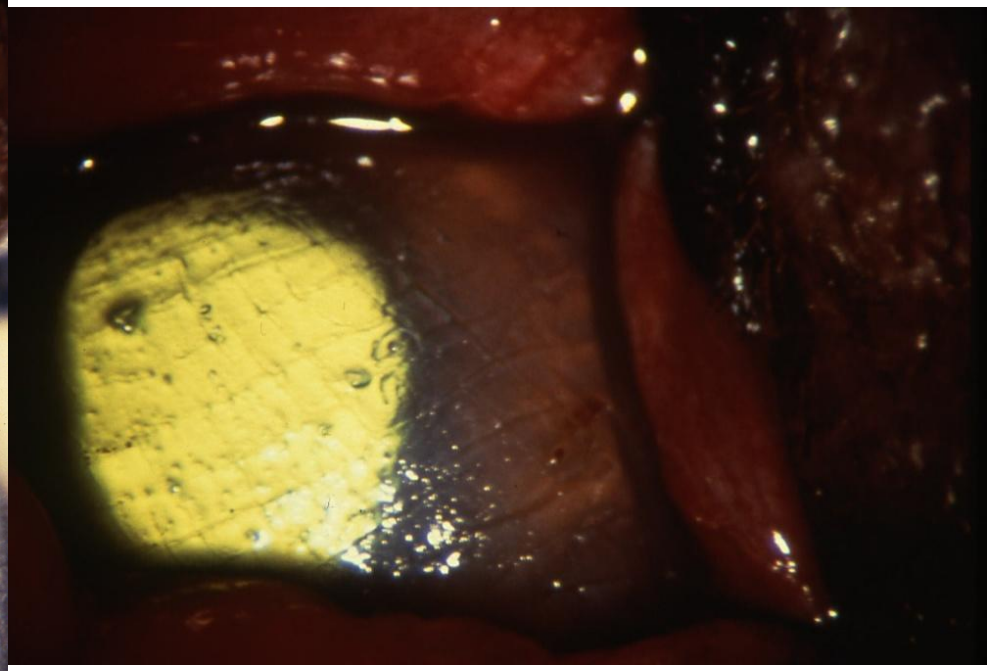

Punctate keratotomy

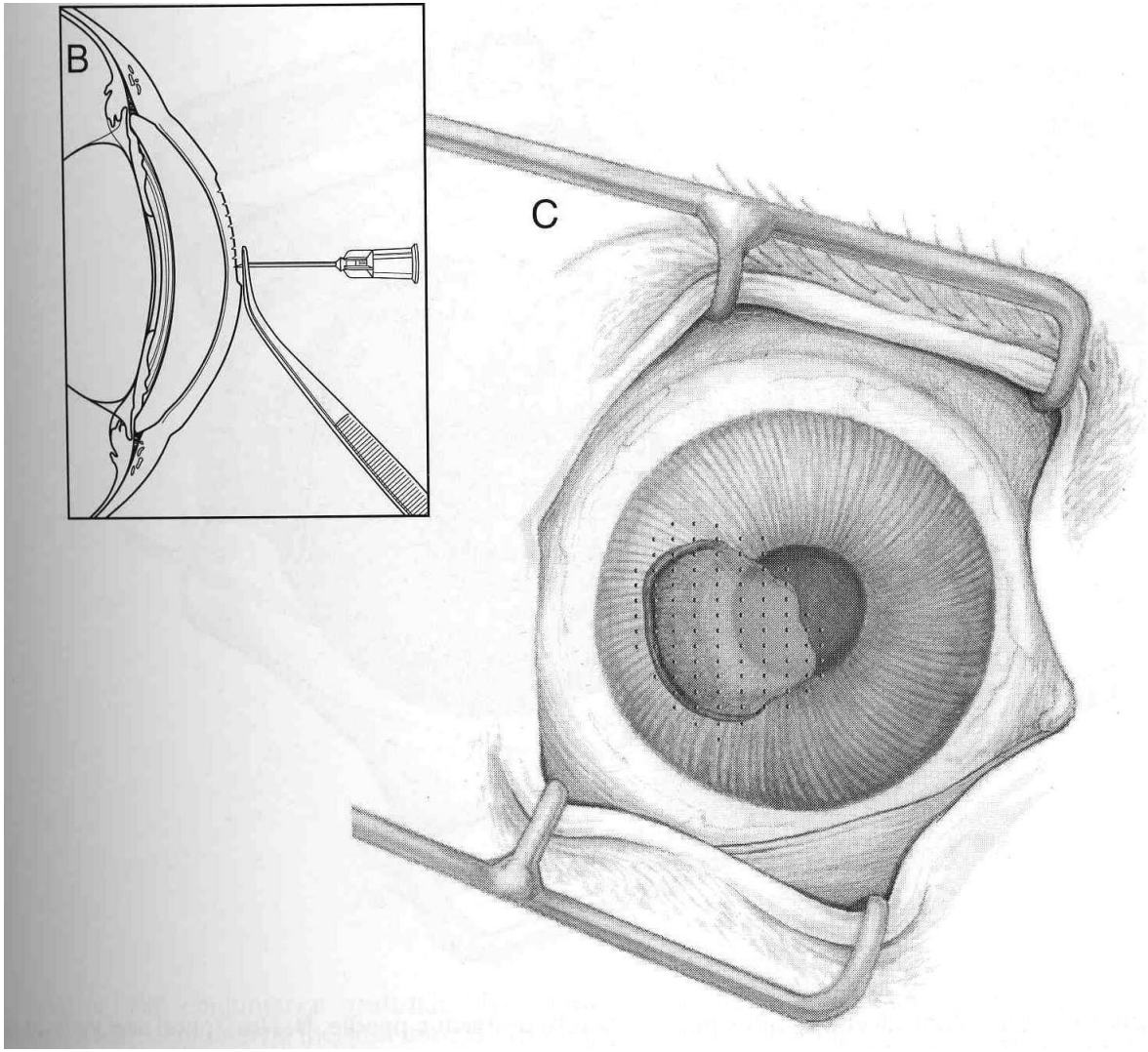

Diamond Burr Keratectomy

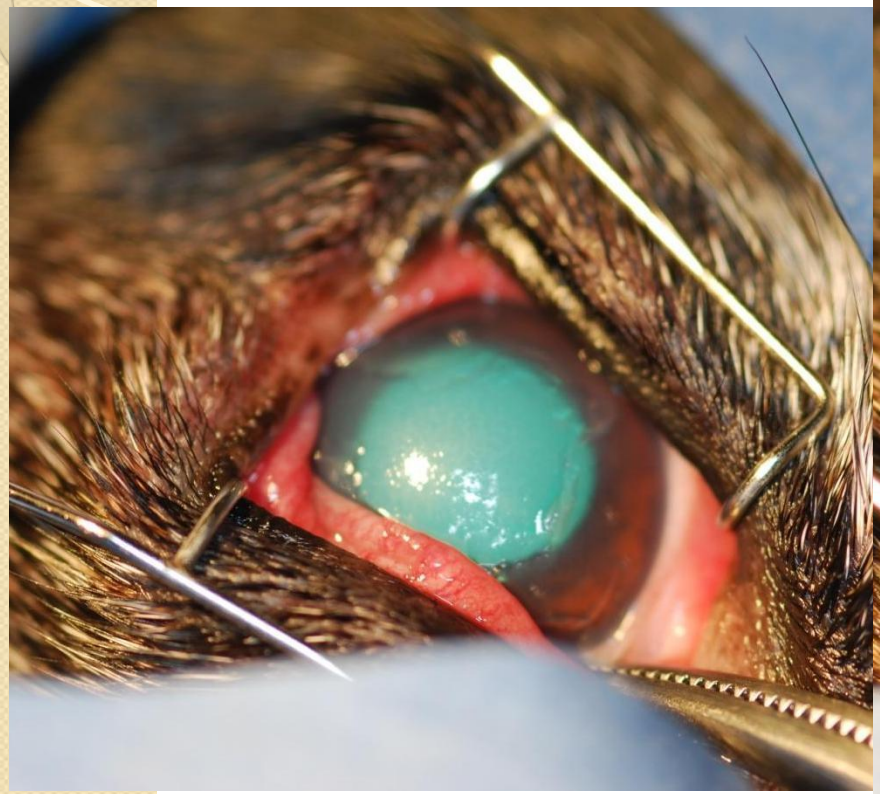

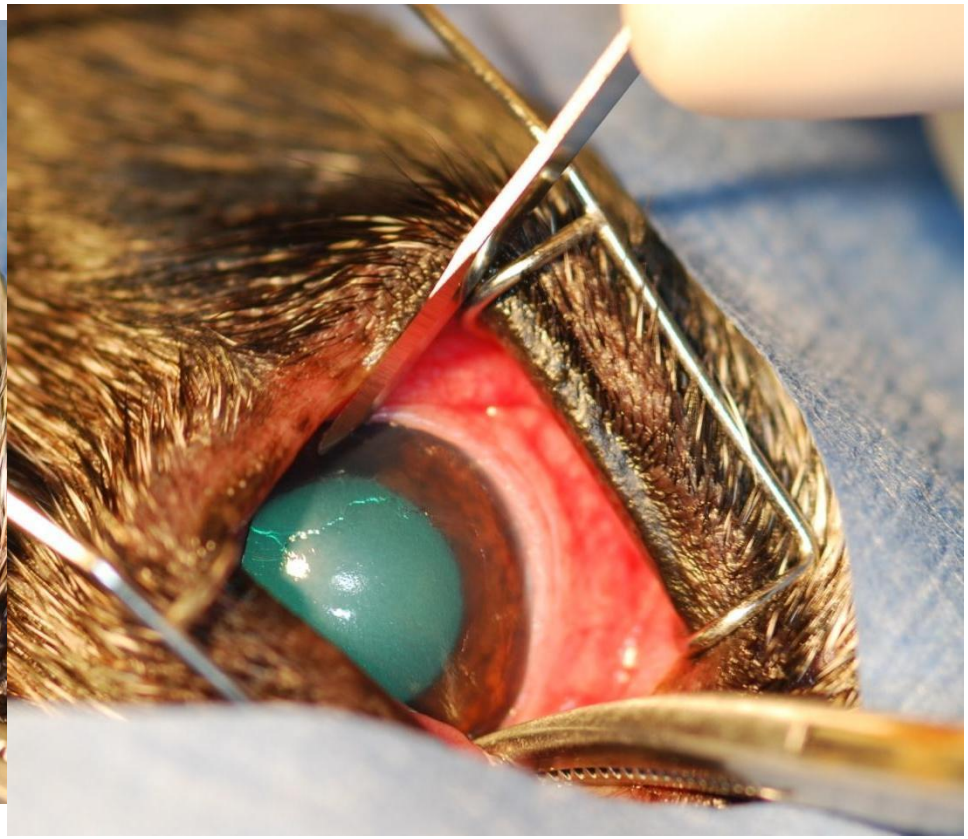

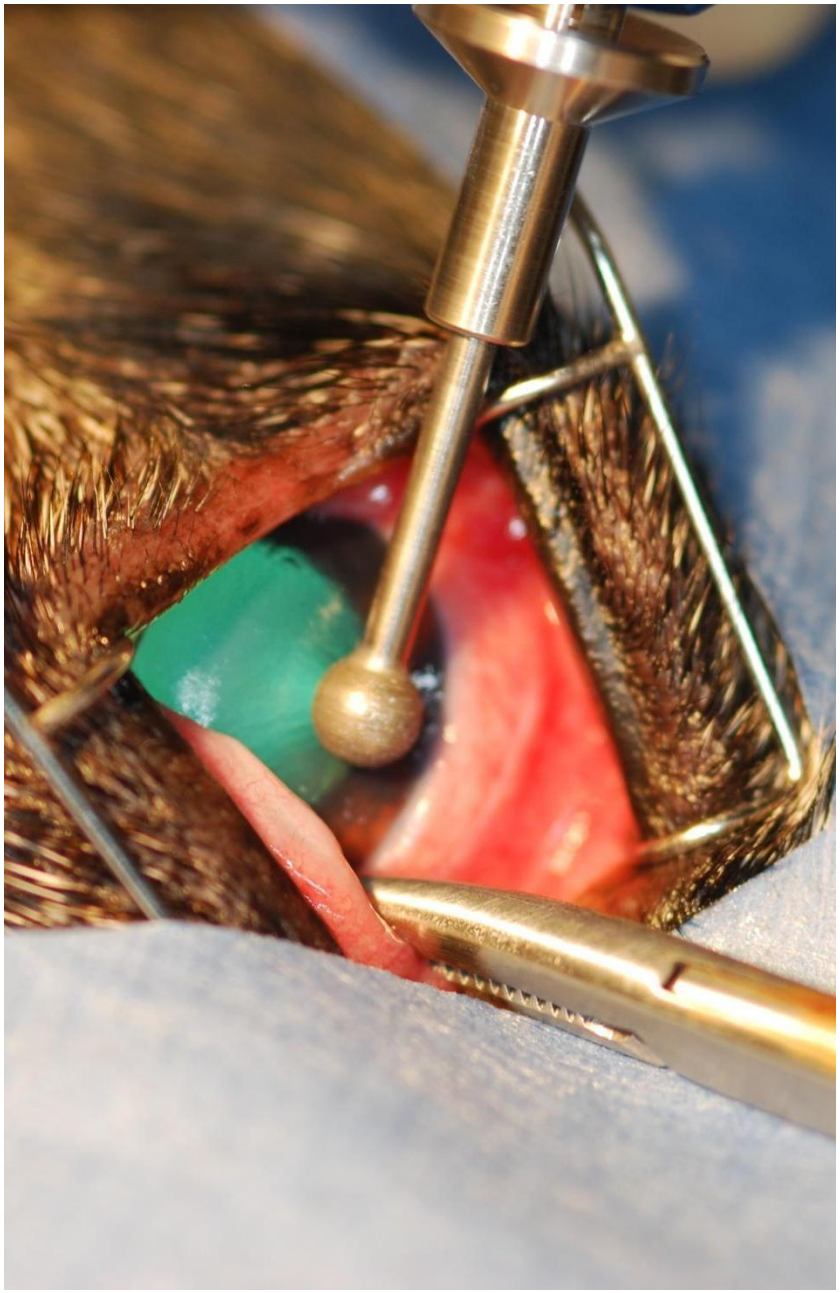

Soft contact lenses

The Final Result

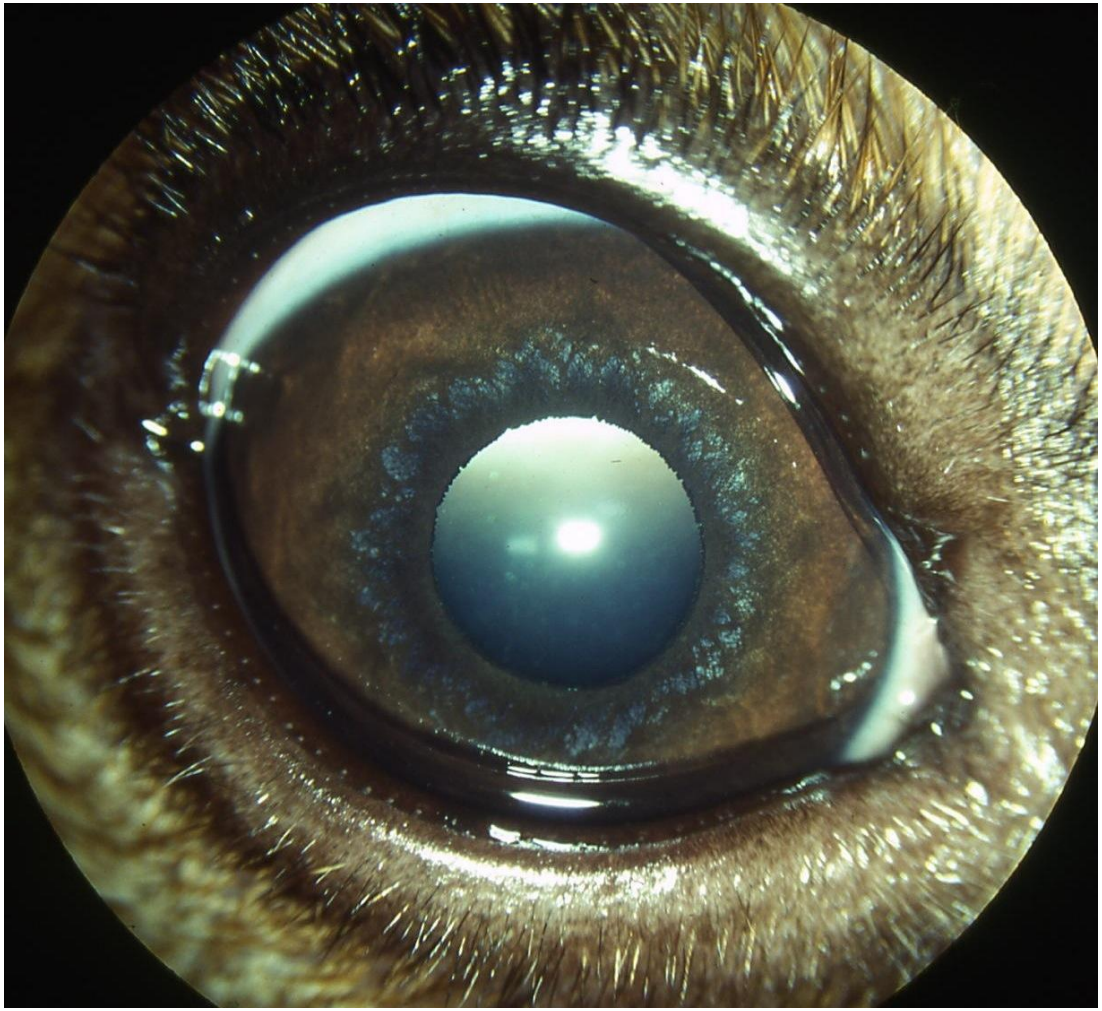

Best Job In The World